The American Journal of Dermatopathology *22(5): 391–396, 2000*

Atypical Histologic Features in Melanocytic Nevi

Carmelo Urso, M.D.

The atypical histologic features considered to be specific to dysplastic (atypical) nevi have been reported to occur in nevi that are common nevi by all other clinical and histologic features. The distribution and mutual relations among such features in nevi need to be further studied. Six histologic features (dimension > 5 mm, lentiginous proliferation, disordered nested pattern, melanocytic dyskaryosis, dermal lymphocytic infiltrate, suprabasal melanocytes) were analyzed in 253 melanocytic nevi with different clinical appearances. Atypical histologic features, found in 72% of nevi, occurred singly or formed numerous and highly variable combinations. Nevi formed a complex histologic spectrum comprising lesions showing a progressively increasing incidence of atypical features rather than two classes (common and dysplastic nevi). To divide the investigated lesions in objectively defined groups, we used a scoring system. In each nevus, a numeric value of 1 was assigned when each of the studied parameters was present and a value of 0 was assigned when each of these parameters was absent; on the basis of the final scores, nevi were divided in six different classes (classes 0–5). Diagnostic categories such as dysplastic nevi and common nevi seem to be inappropriate, as they do not reflect the real histologic complexity of such lesions.
Key Words: Dysplastic nevus—Melanocytic nevus—Nevus.

From the Dermatopathology Section, S.M. Annunziata Hospital, Florence, Italy.

Address correspondence and reprint requests to C. Urso, M.D., Dermatopathology Section, S.M. Annunziata Hospital, I-50011 Antella, Florence, Italy.

Since 1978, some melanocytic lesions first observed in patients with familial melanoma (B-K moles) and shortly afterward in patients with nonfamilial melanoma as well as individuals in the general population (dysplastic nevi) have been proposed as risk markers for and precursors of melanoma (1–3). A dysplastic (atypical) nevus, considered to be a distinct clinicopathologic entity (2,3), has been clinically defined as a macular or papulomacular lesion that is larger than 5 mm, variable in size, variegated in color, and has ill-defined borders (4,5). Histologically, it has been reported to be characterized by a set of atypical features, including 1) radial extension of the intraepidermal component beyond the dermal component (3–7); 2) lentiginous melanocytic proliferation or hyperplasia (4,5,8,9); 3) proliferation of disordered nests, (i.e., marked junctional proliferation plus irregular nests plus bridging) (3–5,7,9,10); 4) melanocytic atypia (3,7,8); and 5) dermal host response (lymphocytic infiltrate, fibrosis, and vascular neoformation) (11,12). Over time, however, it has become progressively apparent that such atypical histologic features are not specific to the dysplastic nevus, because they may occur in other nevi that by all other clinical and histologic criteria are common nevi (13–15); conversely, they may be absent in clinically atypical lesions (13,16). Such a poor correlation between clinical phenotype and histologic appearance tends to flaw the concept of dysplastic nevus as a real clinicopathologic entity. Moreover, the occurrence of atypical features in clinically benign nevi highlights the problem of the histologic distinction between dysplastic nevus and common nevus (17). This distinction is crucial to histopathologists, who consider dysplastic nevi to indicate patients with an increased risk of developing melanoma (at contiguous or noncontiguous sites), whereas common nevi would confer no particular risk (1–3).

The aims of this study were 1) to analyze the distribution of atypical histologic features considered to be specific to the dysplastic nevus in a series of melanocytic nevi with different clinical appearances; 2) to investigate the existing, if any, relations among them; and 3) to establish whether nevi really consist of two distinct classes of lesions (common nevi and dysplastic nevi) and

whether such classes can be reliably diagnosed by histopathologic examination.

MATERIALS AND METHODS

Two-hundred sixty-six consecutive melanocytic nevi from 228 patients submitted to the Dermatopathology Section of S.M. Annunziata Hospital (Florence, Italy) over a period of 6 months were examined. Surgical specimens were fixed in 10% buffered formalin and embedded in paraffin; sections were stained with hematoxylin and eosin. Eight nevi from 7 patients were examined in consultation during the same period. Three lesions had been excised from 2 patients with melanoma (SSM, level II, 0.58 mm; SSM, level III, 1.30 mm). Clinically atypical lesions were excised to exclude melanoma, and clinically benign nevi were removed at the patients' request for cosmetic reasons. The 274 lesions were histologically reviewed without benefit of the clinical information. Twenty-one nevi exemplifying specific diagnoses (3 Spitz nevi, 5 Reed nevi, 11 blue nevi, and 2 Sutton nevi) were excluded; thus, the group studied consisted of 253 lesions. Clinically, the nevi in the study set had different appearances; some were said to have color variegation and/or ill-defined borders, and others were reported as uniformly brown with regular and well-defined borders. Histologically, junctional and compound nevi showed nests of round or occasionally spindle-shaped melanocytes at the dermoepidermal junction, sometimes with an increase in single melanocytes in the basal epidermis between nests. Compound and intradermal nevi showed dermal melanocytes as single cells in cords, sheets, or nests, without atypia or mitoses. Some compound and intradermal nevi were exophytic in the shape of a fibroepithelial polyp or papilloma (Unna nevi), or dome-shaped and predominantly endophytic (Miescher nevi). Some nevi were flat and characterized by melanocytes arranged mostly in nests at the dermoepidermal junction. Some were slightly elevated with nests confined to the dermoepidermal junction and papillary dermis. The junctional component tended to extend for a number of rete ridges beyond the intradermal component of the nevus (Clark junctional and compound nevi) (18).

In each lesion, the following six histologic features considered to be specific to dysplastic nevi were evaluated:

1. Dimension greater than 5 mm, measured on histologic slides (lesions were sectioned through the longest axis).
2. Lentiginous proliferation, defined as an increased number of melanocytes appearing as single units at the dermoepidermal junction with elongation of the rete ridges (4,5,8,9) (Fig. 1).

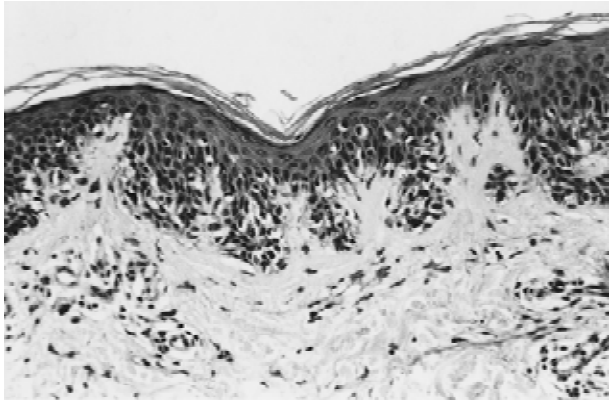

FIG. 1. Lentiginous proliferation and suprabasal melanocytes. Melanocytes appear as single units at the dermoepidermal junction. A small number of cells are located in the spinous layer (pseudoinfiltration)(hematoxylin-eosin, ×200).

3. Disordered nest proliferation, defined as an increased number of melanocytes aggregating in junctional nests, which were variable in size, shape, and orientation; tending to confluence; and producing bridging (3–5,7,9,10) (Fig. 2).
4. Melanocytic dyskaryosis or atypia, defined as melanocytic nuclei more enlarged than keratinocytic nuclei and pleomorphic (oval, spindle, and/or semilunar in shape; variable in size) (3,7,8) (Fig. 3).
5. Dermal lymphocytic infiltrate, defined as a dermal lymphocytic infiltrate underlying the melanocytic proliferation (11,12) (see Fig. 2).
6. Suprabasal melanocytes, consisting of the occasional presence of a small number of cells generally appearing as solitary units in the spinous layer without effacement of epidermal architecture (pseudoinfiltration) (19–22) (see Fig. 1).

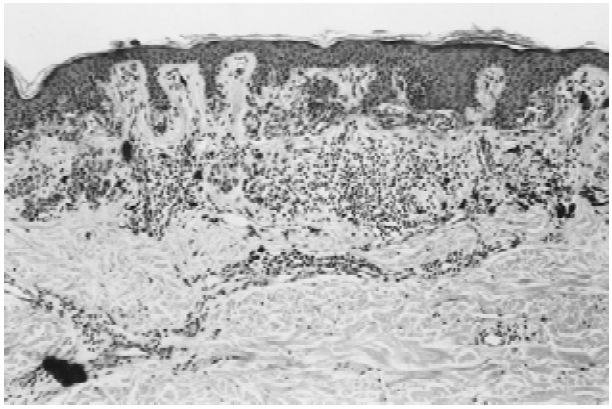

FIG. 2. Proliferation of disordered nests and dermal lymphocytic infiltrate. Variably shaped melanocytic nests tend to confluence, producing bridging. In the dermis, numerous lymphocytes mixed with nevus cells and melanophages (hematoxylin-eosin, ×100).

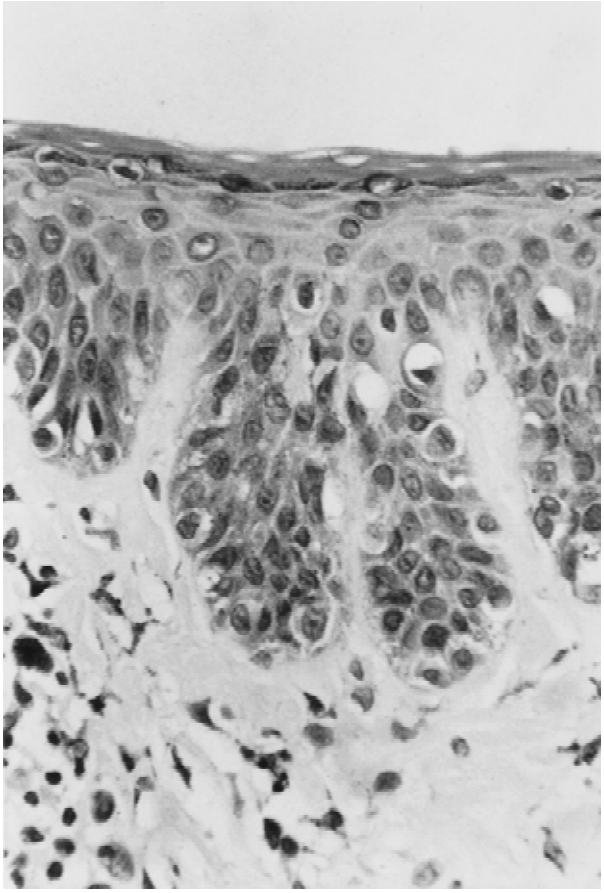

FIG. 3. Dyskaryosis. Junctional melanocytes with enlarged and slightly irregular nuclei (hematoxylin-eosin, ×400).

Arbitrarily, lentiginous proliferation, disordered nest proliferation, and a dermal lymphocytic infiltrate were considered to be present when they involved at least three adjacent rete ridges.

A scoring system was used. In each nevus, a numeric value of 1 was assigned when each of the abovementioned parameters was present; a value of 0 was given when each of them was absent. A final score ranging from 0 to 6, resulting from the sum of the values obtained, was assigned to each lesion.

To evaluate the correlation between histopathologic characteristics and clinical phenotype, the following clinical parameters were considered: asymmetry, irregular border, ill-defined border, and color variegation. Nevi were divided in three clinical groups: nevi without clinical atypia (A) when none of the clinical parameters that we investigated were found, nevi with mild clinical atypia (B) when one or two of the parameters were found, and nevi with severe clinical atypia (C) when more than two of the parameters were found. The correlation between histopathologic and clinical features was studied using the Cohen k statistic:

$$k = \frac{lo - le}{1 - le}$$

where lo is the observed concordance and le is the expected concordance. The k statistic incorporates a correction for the extent of agreement expected by chance alone. In the statistics literature, k values less than 0.40 are considered to represent poor agreement, values ranging from 0.40 to 0.75 represent fair to good agreement, and values greater than 0.75 represent excellent agreement (23).

RESULTS

In the series of 253 nevi examined, 26 were junctional, 114 were compound, and 113 were intradermal. In the 227 compound and intradermal nevi, 193 showed a dermal component consisting of small rounded dermal nevus cells arranged in cords and nests in the papillary dermis, without specific characteristics referable to a special type of nevus, whereas the remaining 34 lesions presented a dermal component showing congenital features (nevus cells disposed in an interstitial or single cell pattern between collagen bundles of at least the upper half of the reticular dermis and in periadnexal, perivascular, and perineural sites).

The analysis of data showed that apart from a group of lesions in which they were absent (70 cases [27.6%]), the features investigated occurred singly or in various combinations. One hundred one nevi (39.9%) were larger than 5 mm, 84 nevi (33.2%) showed lentiginous proliferation, 43 nevi (17.0%) showed disordered nests, 41 cases (16.2%) showed melanocytic dyskaryosis, 20 nevi (7.9%) showed a dermal lymphocytic infiltrate, and 18 lesions (7.1%) showed suprabasal melanocytes. Lentiginous proliferation and a disordered pattern of nests were associated in 19 nevi. Melanocytic dyskaryosis occurred alone only once; it was associated with lentiginous proliferation in 15 cases, with disordered nest proliferation in 14 cases, and with both in 11 cases. A dermal lymphocytic infiltrate occurred alone only once; it was in association with lentiginous proliferation in 11 cases, with disordered nest proliferation in 3 cases, and with both in 5 cases. Suprabasal melanocytes occurred as the only atypical feature in 1 case, with lentiginous proliferation in 7 cases, with disordered nest proliferation in 5 cases, and with both in 5 cases. As a whole, nevi seemed to form a spectrum comprising lesions showing a progressively increasing incidence of atypical features. Using the scoring system, lesions were divided in six classes (Table 1).

Class 0 consisted of 70 lesions in which none of the features investigated were found: 9 showed congenital features.

Class 1 consisted of 112 nevi showing only one of the

TABLE 1. *Final scores and classes of 253 melanocytic nevi*

Score/class	0	1	2	3	4	5	6
Lesions							
JN (n = 26)	—	17	5	2	1	1	—
CN (n = 114)	17	35	30	21	8	3	—
IN (n = 113)	53	60	—	—	—	—	—
Total (%)	70 (27.5%)	112 (44.2%)	35 (15.1%)	23 (9.1%)	9 (3.5%)	4 (1.5%)	—

JN, junctional nevi; CN, compound nevi; IN, intradermal nevi.

features investigated: 72 were larger than 5 mm (22 showed congenital features), 32 had lentiginous proliferation, 6 had disordered nest proliferation, 1 had melanocytic dyskaryosis, and 1 had suprabasal melanocytes.

Class 2 comprised 35 cases in which two parameters were identified. Eleven nevi were larger than 5 mm: 8 had lentiginous proliferation (2 showed congenital features), 2 had disordered nest proliferation, and 1 had a dermal lymphocytic infiltrate. Twenty-four nevi were 5 mm or smaller and presented with a lentiginous proliferation together with melanocytic dyskaryosis (8 cases), lentiginous proliferation together with a dermal lymphocytic infiltrate (6 cases), lentiginous proliferation and disordered nest proliferation (4 cases), disordered nest proliferation and melanocytic dyskaryosis (4 cases), and lentiginous proliferation and suprabasal melanocytes (2 cases).

Class 3 included 23 nevi displaying three parameters. Nine nevi were larger than 5 mm: 4 showed disordered nest proliferation and melanocytic dyskaryosis, 2 showed lentiginous proliferation and suprabasal melanocytes, 1 showed lentiginous proliferation and melanocytic dyskaryosis, 1 showed lentiginous proliferation and a dermal lymphocytic infiltrate, and 1 showed disordered nest proliferation and a dermal lymphocytic infiltrate. Fourteen lesions were 5 mm or smaller: 4 showed lentiginous proliferation, disordered nest proliferation, and a dermal lymphocytic infiltrate; 3 showed lentiginous proliferation, disordered nest proliferation, and melanocytic dyskaryosis; 3 showed lentiginous proliferation, melanocytic dyskaryosis, and a dermal lymphocytic infiltrate; 2 showed lentiginous proliferation, melanocytic dyskaryosis, and suprabasal melanocytes; and 2 showed disordered nest proliferation, melanocytic dyskaryosis, and suprabasal melanocytes.

Class 4 comprised nine lesions in which four of the parameters studied were present. All showed disordered nest proliferation and melanocytic dyskaryosis. Two lesions also showed a greatest dimension more than 5 mm and lentiginous proliferation, two nevi showed lentiginous proliferation and suprabasal melanocytes, two nevi showed a greatest dimension more than 5 mm and suprabasal melanocytes, one nevus showed a dermal lymphocytic infiltrate and suprabasal melanocytes, one nevus showed lentiginous proliferation and a dermal lymphocytic infiltrate, and one nevus (with congenital features) had a dimension more than 5 mm and a dermal lymphocytic infiltrate.

Class 5 consisted of four nevi showing five of the features investigated: all nevi were larger than 5 mm and showed lentiginous proliferation, melanocytic dyskaryosis, and suprabasal melanocytes; three also showed disordered nest proliferation; and one showed a dermal lymphocytic infiltrate.

No nevi showed all six of the parameters studied (class 6).

Because four of the six parameters investigated were intraepidermal, the 113 intradermal nevi had a lower score than junctional and compound nevi: 53 scored 0 and 60 scored 1. Of the 140 junctional and compound nevi, 17 were assigned to class 0 (12.1%), 52 to class 1 (37.1%), 35 to class 2 (25.0%), 23 to class 3 (16.4%), 9 to class 4 (6.5%), and 4 to class 5 (2.9%). Of the 34 nevi with congenital features, 9 (1 compound and 8 intradermal) were assigned to class 0, 22 (3 compound and 19 intradermal) to class 1, 2 (compound) to class 2, and 1 (compound) to class 4. The 3 nevi from melanoma patients were assigned to classes 0, 2, and 4, respectively.

The results of correlation of histopathologic and clinical parameters are shown in Table 2. In class 0, more than 50% of nevi were without atypia, 35% showed mild atypia, and 12.8% had severe atypia. In class 1, nevi showed a similar trend (48.2%, 37.5%, and 14.3%, respectively). Class 2 nevi did not show clinical atypia in 20.0% of cases; they showed mild atypia in 48.6% of cases and severe clinical atypia in 31% of cases. In class 3, 17.4% of nevi showed no clinical atypia, 56.5% dis-

TABLE 2. *Relationship between histologic and clinical features in 253 melanocytic nevi*

Class	A	B	C	Total
0	36 (51.4%)	25 (35.8%)	9 (12.8%)	70
1	54 (48.2%)	42 (37.5%)	16 (14.3%)	112
2	7 (20.0%)	17 (48.6%)	11 (31.4%)	35
3	4 (17.4%)	13 (56.5%)	6 (26.1%)	23
4	1 (11.1%)	3 (33.3%)	5 (55.6%)	9
5	—	2 (50.0%)	2 (50.0%)	4
Total	102 (40.35)	102 (40.3%)	49 (19.4%)	253

A, nevi without clinical atypia; B, nevi with mild clinical atypia; C, nevi with severe clinical atypia.

played mild atypia, and 26% had severe atypia. Only one class 4 nevus was not atypical; 33.3% showed mild atypia, and 55.6% had severe atypia. In class 5, two of four nevi had mild atypia, and two of four showed severe atypia.

For the statistical evaluation, the six classes were divided in three groups analogous to the clinical groups: class 0 represented nevi without atypical histologic features, classes 1 and 2 represented nevi with one or two atypical histologic features, and classes 3 through 5 represented nevi with more than two atypical histologic features. The statistical analysis showed a poor overall concordance of histologic and clinical parameters (k [overall] = 0.08, SE = 0.04; k [class 0] = 0.13, SE = 0.06; k [classes 1–2] = 0.00, SE = 0.06; k [classes 3–5] = 0.17, SE = 0.06).

DISCUSSION

The atypical features considered to be specific to dysplastic nevi (dimension > 5 mm, lentiginous proliferation, disordered nest proliferation, melanocytic dyskaryosis, dermal lymphocytic infiltrate, suprabasal melanocytes) were investigated in a series of 253 melanocytic nevi. Radial extension was not considered, because it is merely a histologic expression of enlargement of the nevus and therefore occurs of necessity in all nevi at one phase of their life (24). It occurs rather frequently in compound lesions and has been considered to be of little significance (19). Melanocytic atypia, consisting of slight to moderate nuclear alterations of melanocytes, was referred to as *dyskaryosis* to stress the difference from the true severe (fully evolved) atypia of melanoma cells (19,24).

Results showed that atypical features occurred singly or in various combinations in a large percentage of nevi (72.3%). To interpret the possible relations among the parameters studied seemed difficult, because the observed combinations of features were numerous and highly variable. Nevi larger than 5 mm basically showed the same histologic features that occurred in smaller nevi and similar combinations of them. Lentiginous growth and a pattern of disordered nests occurred quite frequently (33% and 17%, respectively), appearing as patterns of different but not mutually exclusive intraepidermal melanocytic growth, because they were associated in 7.5% of cases. Melanocytic dyskaryosis, rarely occurring as a single feature, was generally found in association with lentiginous proliferation (6%), disordered nest proliferation (5.5%), or both such features (4%) according to results from previous studies (19). Similarly, a dermal lymphocytic infiltrate was observed in association with the same parameters: lentiginous proliferation (4%), disordered nest proliferation (1%), or both (2%). Results also showed that nevi (showing 32 different combinations of features) did not form two homogeneous and distinct classes of lesions (common nevi and dysplastic nevi) but a large histologic spectrum consisting of lesions showing a progressively increasing incidence of atypical features. In such a context, which was more complex than expected, it seemed arbitrary to establish a hierarchy of value among the different features (i.e., classification as major and minor features) (25) or among the different combinations. In particular, it seemed histologically impossible to fix a border between nevi implying and nevi not implying an increased melanoma risk (24). Therefore, a scoring system was used in this study to obtain objectively defined classes of lesions. In each nevus, an equal numeric value was assigned to each selected feature, because there was no evidence that one feature might be more significant than another. The features were evaluated by a dichotomic method (present = 1, absent = 0) to avoid subjective evaluations (e.g., slight, moderate, severe dyskaryosis). Using such a system, nevi seemed to form a spectrum ranging from lesions not showing atypical features (class 0) to lesions showing five atypical features (class 5). In the spectrum, the class number seemed to serve as an index of the relative position of the lesion. Clinicopathologic correlation demonstrated that nonatypical nevi showed a progressive decrease of prevalence from the lowest class to the highest class, representing 51.4% of class 0 nevi and 0.0% of class 5 nevi; conversely, nevi with severe clinical atypia showed a progressive increase of prevalence, representing 12.8% of class 0 nevi and 50% to 55% of class 4 and 5 nevi. No particular trend was observed in nevi with mild clinical atypia; however, the overall concordance between histopathologic and clinical parameters was poor (k = 0.08) as in previous studies (13,26), probably because irregularity of clinical aspects does not depend directly on the atypical histologic features studied.

The results confirmed that the histologic features proposed as diagnostic of dysplastic nevus are not specific, because they can be observed in different numbers and various combinations in nevi that are not classifiable as dysplastic nevi by other clinical and histologic criteria. Such lesions include common nevi (13–15,24) and congenital nevi (27–30). Furthermore, recent articles have reported that atypical features occur in a large variety of other nevi (e.g., Spitz nevi, pigmented spindle cell nevi, acral nevi, genital nevi, halo nevi, nevi spili, combined blue nevi, neuronevi) (29,30), suggesting that each type of nevus may show a dysplastic variant (30). If atypical histologic features are present in any type of melanocytic nevus with a junctional component (29,30) and if numerous "dysplastic nevi" seem to exist (30), the concept of dysplastic nevus as a distinct histologic entity can hardly be supported. As previous studies have pointed out, when rigorously analyzed, nevi, rather than two distinct

histologically recognizable groups of lesions, form a continuous spectrum (17,24,29); thus, the diagnostic categories of common and dysplastic nevi seem inadequate. The existence of a continuous spectrum of nevi may explain why the diagnosis of dysplastic nevi has seemed to be difficult and poorly reproducible in daily histologic practice (22). This could also explain in part the controversy that has arisen on this topic (21). In fact, the spectrum of nevi encompasses lesions that might be called common and dysplastic nevi using traditional labels (probably located at the extremes) but also includes a large and heterogeneous group of nevi with intermediate characteristics that do not fit either of the two diagnostic categories. The clinical significance and implications of the different lesions that constitute such a complex spectrum must be clarified by further studies. Meanwhile, it seems reasonable to discontinue the use of the diagnostic categories of common nevi and dysplastic nevi, which do not reflect the real histologic complexity of nevi, and to search for different diagnostic approaches (24,29). A prudent approach may be to diagnose nevi as junctional, compound, and dermal, reporting any atypical characteristic (i.e., dimension > 5 mm, lentiginous proliferation, disordered nest proliferation, melanocytic dyskaryosis, dermal lymphocytic infiltrate, suprabasal melanocytes) if present (analytic diagnosis). The relative class number may be added to indicate the objective position of the lesion in the spectrum that nevi seem to form.

REFERENCES

1. Clark WH, Jr, Reimer RR, Greene M, et al. Origin of familial melanoma from heritable melanocytic lesions. The B-K mole syndrome. *Arch Dermatol* 1978;114:732–8.
2. Elder DE, Goldman LI, Goldman SC, et al. The dysplastic nevus syndrome: a phenotypic association of sporadic cutaneous melanoma. *Cancer* 1980;46:1787–94.
3. Elder DE, Clark WH, Elenitsas R, et al. The early and intermediate precursor lesions of tumor progression in the melanocytic system: common acquired nevi and atypical (dysplastic) nevi. *Semin Diagn Pathol* 1993;10:18–35.
4. NIH Consensus Conference. Precursors to malignant melanoma. *JAMA* 1984;251:1864–6.
5. NIH Consensus Conference. Diagnosis and treatment of early melanoma. *JAMA* 1992;268:1314–9.
6. Clark WH, Jr, Elder DE, Guerry D IV, et al. A study of tumor progression: the precursor lesions of superficial spreading and nodular melanoma. *Hum Pathol* 1984;15:1147–65.
7. Ackerman AB, Mihara I. Dysplasia, dysplastic melanocytes, dysplastic nevi, the dysplastic nevus syndrome, and the relation between dysplastic nevi and malignant melanoma. *Hum Pathol* 1985; 16:87–91.
8. Elder DE, Green MH, Guerry D IV, et al. The dysplastic nevus syndrome. Our definition. *Am J Dermatopathol* 1982;4:455–9.
9. Seywright MM, Doherty VR, MacKie RM. Proposed alternative terminology and subclassification of so-called "dysplastic nevi." *J Clin Pathol* 1986;39;189–94.
10. de Wit PEJ, vant Hof-Grootenboer B, Ruiter DJ, et al. Validity of the histopathological criteria used for diagnosis of dysplastic nevi. An interobserver study by the pathology subgroup of the EORTC Malignant Melanoma Cooperative Group. *Eur J Cancer* 1993; 29A:831–9.
11. Balkau D, Gartmann H, Wischer W, et al. Architectural features in melanocytic lesions with cellular atypia. *Dermatologica* 1988;177: 129–37.
12. Steijlen PM, Bergman W, Hermans J, et al. The efficacy of histopathological criteria required for diagnosing dysplastic nevi. *Histopathology* 1988;12:289–300.
13. Carli P, Urso C, De Giorgi V, et al. Sensitivity and specificity of clinical criteria in the detection of histologic atypia in nevi. *Eur J Dermatol* 1994;4:35–9.
14. Klein LJ, Barr RJ. Histologic atypia in clinically benign nevi. A prospective study. *J Am Acad Dermatol* 1990;22:275–82.
15. Cochran AJ, Bailly C, Paul E, et al. *Melanocytic tumors. A guide to diagnosis*. Philadelphia: Lippincott-Raven, 1997:75–89.
16. Roush GC, Dubin N, Barnhill RL. Prediction of histologic melanocytic dysplasia from clinical observation. *J Am Acad Dermatol* 1993;29:555–62.
17. Cook MG, Fallowfield ME. Dysplastic naevi–an alternative view. *Histopathology* 1990;16:29–35.
18. Ackerman AB, Magana-Garcia M. Naming acquired melanocytic nevi. Unna's, Miescher's, Spitz's, Clark's. *Am J Dermatopathol* 1990;12:193–209.
19. Barnhill RL, Roush GC, Duray PH. Correlation of histologic architectural and cytoplasmic features with nuclear atypia in atypical (dysplastic) nevomelanocytic nevi. *Hum Pathol* 1990;21:51–8.
20. Urso C, Giannini A, Bartolini M, et al. Histological analysis of intraepidermal proliferations of atypical melanocytes. *Am J Dermatopathol* 1990;12:150–5.
21. Roth ME, Grant-Kels JM, Ackerman AB, et al. The histopathology of dysplastic nevi. Continued controversy. *Am J Dermatopathol* 1991;13:38–51.
22. Hastrup N, Clemmensen OJ, Spaun E, et al. Dysplastic naevus: histological criteria and their inter-observer reproducibility. *Histopathology* 1994;24:503–9.
23. Cohen J. A coefficient of agreement for nominal scales. *Educ Psychol Meas* 1960;20:37–46.
24. Urso C, Bondi R. The histologic spectrum of acquired nevi. An analysis of the intraepidermal melanocytic proliferation in common and dysplastic nevi. *Pathol Res Pract* 1994;190:609–14.
25. Clemente C, Cochran AJ, Elder DE, et al. Histopathologic diagnosis of dysplastic nevi: concordance among pathologists convened by the World Health Organization Melanoma Programme. *Hum Pathol* 1991;22:313–9.
26. Piepkorn M, Meyer LJ, Goldgar D, et al. The dysplastic melanocytic nevus: a prevalent lesion that correlates poorly with clinical phenotype. *J Am Acad Dermatol* 1989;20:407–15.
27. Rhodes AR, Silverman RA, Harrsit TJ, et al. A histologic comparison of congenital and acquired nevomelanocytic nevi. *Arch Dermatol* 1985;121:1266–73.
28. Marchesi L, Naldi L, Locati F, et al. Combined Clark's nevus. *Am J Dermatopathol* 1994;16:364–71.
29. Barnhill RL. Melanocytic nevi and tumor progression: perspectives concerning histomorphology, melanoma risk and molecular genetics. *Dermatology* 1993;187:86–90.
30. Toussaint S, Kamino H. Dysplastic changes in different types of melanocytic nevi. A unifying concept. *J Cutan Pathol* 1999;26: 84–90.