Carcinomas of Sweat Glands

Report of 60 Cases

Carmelo Urso, MD; Roberto Bondi, MD; Milena Paglierani, BS; Adriana Salvadori, MD; Chiara Anichini, MD; Augusto Giannini, MD

• ***Context.*—Several aspects of sweat gland carcinomas (incidence, classification, diagnosis, and behavior) have not been definitively clarified and need to be studied further.**

***Objective.*—The clinicopathologic findings of a large series of sweat gland carcinomas, collected during a period of 15 years, are presented.**

***Methods.*—Sixty sweat gland carcinomas (41 porocarcinomas, 3 syringomatous carcinomas, 8 ductal carcinomas, 5 adenoid cystic carcinomas, and 3 mucinous carcinomas) were analyzed histologically and immunohistochemically.**

***Results.*—Porocarcinomas were composed of eosinophilic and clear atypical cells arranged in solid-cystic lobular masses. These tumors were divided into 2 subgroups: horizontal porocarcinomas, showing a prominent intraepidermal component, and nodular porocarcinomas, which demonstrated predominant nodular growth. Syringomatous carcinomas presented keratinizing and nonkeratinizing cysts, dilated tubules (sometimes with a "tadpole" appearance), small neoplastic ducts, solid islands, and cellular cords. Ductal carcinomas were characterized by a prominent formation of tubules, solid islands, and cellular cords. Adenoid cystic carcinomas presented a characteristic pattern, showing basaloid monomorphous cells with moderately atypical nuclei, arranged in cribriform or solid islands and in tubular structures. Mucinous carcinomas were composed of moderately atypical cells with eosinophilic vacuolated cytoplasm, forming solid and cystic islands floating in large mucin pools. Immunohistochemically, cytokeratin was found in neoplastic cells in all cases, carcinoembryonic antigen was detected in 73% of cases, and actin-positive (myoepithelial) cells were not found.**

***Conclusions.*—Although numerous studies have been published in recent years, the histologic features, histogenesis, and classification of sweat gland carcinomas still remain controversial and need to be clarified by further studies.**

(*Arch Pathol Lab Med.* 2001;125:498–505)

Although the first commonly accepted case was reported by V. Cornil as early as 1865,[1] sweat gland carcinomas were still surrounded by mystery at the beginning of the 1950s, because few cases had been described and these were not well documented. In 1943, reviewing the world literature up to 1939, Gates et al[1] counted only 29 descriptions of sweat gland carcinomas, 8 of which had been reported in the 1800s. In 1951, Stout and Cooley[2] opened the modern era of pathology of sweat gland carcinomas, giving a precise definition of such tumors. They reported 11 well-documented new cases, including 6 tumors that had metastasized and 5 that showed extensive local growth only.[2] The authors also provided descriptions of particular histologic types of tumors, such as adenoid cystic carcinoma, mucinous carcinoma, and ductal carcinoma.[3] The first classification of sweat gland carcinomas, however, dates back only to 1968, when Berg and McDivitt[4] presented the largest series found in the literature (101 tumors) and proposed a classification system paralleling that used for sweat gland adenomas. In recent decades, although numerous studies on this subject have been published,[3,5–17] many aspects of carcinomas of sweat glands (eg, their incidence, classification, diagnosis, and behavior) still remain obscure. Previous publications have attributed such difficulties to objective causes, such as the relative rarity of such neoplasms, their resemblance to some metastatic visceral carcinomas, the too-wide range of their histologic appearances, and the confusing terminology used by various authors.[10,11,16]

In this article, we report 60 cases of sweat gland carcinomas, which were collected over a period of 15 years.

MATERIALS AND METHODS

Fifty-six cases of sweat gland carcinomas were collected at the Institute of Anatomic Pathology, University of Florence, Italy (January 1, 1984 through December 31, 1994) and at the Department of Anatomic Pathology, Dermatopathology Section, S. M. Annunziata Hospital, ASL 10 of Florence, Italy (January 1, 1995 through December 31, 1998). Four cases had been sent for consultation to 2 of the authors (C.U., R.B.) during the same periods. Twelve tumors (cases 9, 42, 46–48, 51, 52, and 56–60) have been described in the literature previously.[16,18–20]

Specimens were fixed in 10% buffered formaldehyde, and paraffin-embedded histologic sections were stained with hematoxylin-eosin. Additional sections were stained with periodic acid–Schiff (PAS), before and after diastase digestion. For immunocytochemical study, sections were mounted on poly-L-lysine (Sigma

Accepted for publication November 28, 2000.

From the Department of Anatomic Pathology, Dermatopathology Section, S. M. Annunziata Hospital, Florence, Italy (Drs Urso, Salvadori, Anichini, and Giannini); and the Institute of Anatomic Pathology, University of Florence, Florence, Italy (Drs Bondi and Paglierani).

Reprints: Carmelo Urso, MD, Department of Anatomic Pathology, Dermatopathology Section, S. M. Annunziata Hospital, I-50011 Antella, Florence, Italy (e-mail: cylaur@tin.it).

Chemical Co, St Louis, Mo)-coated glass slides and dried overnight at 37°C, then were dewaxed, hydrated, and treated with 0.4% hydrogen peroxidase in absolute methanol for 15 minutes at room temperature to block endogenous peroxidase activity. Subsequently, the sections were washed in phosphate-buffered saline (pH 7.4) and treated with normal horse serum (Vector Laboratories, Burlingame, Calif) for 20 minutes to reduce background staining. Three primary antibodies were used: monoclonal anti–α-smooth muscle actin, clone 1A4 (dilution 1:2000; Sigma); anti–human cytokeratin, clone CAM 5.2 (Becton Dickinson, San Jose, Calif); and monoclonal mouse anti–carcinoembryonic antigen (CEA), clone 2C23 (Zymed Laboratories, San Francisco, Calif). After being washed in phosphate-buffered saline, sections were incubated with biotinylated horse anti-mouse IgG (dilution 1:200; Vector) for 30 minutes at room temperature. After washing, they were treated with avidin-biotin-peroxidase complex (Vector) for 30 minutes at room temperature. As a final indicator, 3,3′-diaminobenzidine (Sigma) was used with Mayer's hematoxylin as the counterstain.

RESULTS

The cases were histologically classified as follows: porocarcinomas (n = 41), syringomatous carcinomas (n = 3), ductal carcinomas (n = 8), adenoid cystic carcinomas (n = 5), and mucinous carcinomas (n = 3).

Porocarcinomas (Cases 1–41)

This series included 23 male and 18 female patients; the average age was 74.3 years (range 12–97 years). Nineteen lesions were located on the head, 2 on the neck, 4 on the upper limb, 1 on the axilla, 4 on the chest, 1 on the abdomen, 2 on the groin, 7 on the lower limb, and 1 in the vulva. Tumors were described as nodular, nodular-ulcerative, vegetative masses, or as infiltrated plaques. Two patients had 1 recurrence, 1 patient had 2 recurrences, 2 patients had lymph node metastases, and 1 patient had both 1 recurrence and lymph node metastases (Table 1).

Histologically, tumors of this series were mainly characterized by solid neoplastic lobular masses or islands, showing cystic cavities due to extensive cellular necrosis (Figure 1). Neoplasms were composed of 2 types of atypical cells: eosinophilic and clear cells. Eosinophilic cells were polyhedral or fusiform with round to oval hyperchromatic nuclei, distinct nucleoli, indistinct cell boundaries, and a variable amount of cytoplasm, which appeared scanty and densely eosinophilic (small eosinophilic cells) or abundant, granular, lightly eosinophilic, and sometimes pale (large eosinophilic cells). Clear cells, observed in 50% of the cases, were large and polyhedral and had round to oval nuclei, abundant clear cytoplasm, and distinct cell borders. Transitions from small eosinophilic to large eosinophilic to clear cells occurred. All neoplasms showed asymmetry of architecture at scanning magnification; 35 displayed infiltrative growth. Tumors presented epidermal contact in 34 cases; epidermal ulceration, scale crust, and focal ductal formation (Figure 2, b and c) in 26 cases; and a comedo-like appearance (Figure 2, a) in 6 cases. Stromal retraction between tumor islands and dermal connective tissue was observed in 12 cases. Dermal infiltration was present in 35 cases, and hypodermal involvement was evident in 10. All cases displayed nuclear atypia. Mitoses were frequent and were particularly prominent in some zones of some tumors. Endolymphatic invasion was observed in 7 cases, acantholysis of tumor cells in 10 cases, squamous whorls in 15 cases, and hyalinized stroma was evident in 7 cases. Case 23 showed marked atypia with numerous multinucleated neoplastic cells; case 30 had evidence of perineural neoplastic involvement. Case 33 was composed almost entirely of clear cells. Case 34 displayed a pagetoid epidermal pattern (Figure 3). An inflammatory infiltrate around neoplastic masses was observed in almost all cases; the infiltrate was composed of lymphocytes and plasma cells, rarely mixed with neutrophils and eosinophils.

On the basis of the architectural models, tumors were divided into 2 subgroups. Subgroup A (cases 1–13) consisted of 13 neoplasms that formed a homogeneous group characterized by the presence of a prominent intraepidermal component and consequently by a predominantly horizontal growth pattern (*horizontal porocarcinomas*) (Figure 4). The intraepidermal portion of the growth was composed of large atypical cells that were arranged in irregular nests and islands, variable in size and in shape, and sharply demarcated from the surrounding epidermal keratinocytes. Six tumors were entirely intraepidermal (cases 1–6), and 7 tumors also showed an infiltrative dermal component, constituted by polymorphous masses and islands of atypical cells. Cells of the intraepidermal islands were identical to those invading the dermis. Subgroup B (cases 14–41) consisted of 28 tumors without a significant intraepidermal component and showing a nodular growth pattern (*nodular porocarcinomas*) (Figure 1, a). Neoplastic cells infiltrated the dermis; were arranged in solid lobular masses, islands, and sheets; and showed cystic spaces that were empty or contained amorphous cellular debris (Figure 1, b). Epidermal contact was observed in 21 cases in this subgroup.

Histochemically, neoplastic cells contained glycogen in 26 cases and intratubular, PAS-positive, diastase-resistant material in 20 cases. Immunohistochemically, tumor cells were positive for cytokeratin and negative for actin. Intraductal CEA-positive material was observed in 23 cases (Table 2). Two neoplasms were associated with a poroma (cases 14 and 15).

Syringomatous Carcinomas (Cases 42–44)

This series included 1 man and 2 women. The average age of the patients was 70.3 years (range 48–84 years). Two tumors, appearing as ulcerative nodules, were located on the lip (cases 42 and 44), and 1 occurred on the eyelid (case 43) (Table 1).

Histologically, these tumors, which were composed of tubules, keratinizing cystic structures, solid islands, cellular cords, and desmoplastic stroma (Figure 5), resembled syringomas and diffusely infiltrated the dermis. All cases showed epidermal contact; 2 cases (cases 42 and 44) showed subcutaneous fat infiltration, but no nuclear atypia or mitoses, whereas case 43 showed slight atypia and few mitoses. Perineural infiltration and hyalinized stroma were found in 2 tumors (cases 42 and 43). Case 42 also showed tubules with a ''tadpole'' appearance, nonkeratinizing cysts, ulceration, and muscular tissue involvement.

Histochemically, all the tumors showed intraluminal, PAS-positive, diastase-resistant material. Immunohistochemically, neoplastic cells were positive for cytokeratin and negative for actin; CEA was found in intratubular material (Table 2).

Ductal Carcinomas (Cases 45–52)

The patients with ductal carcinoma included 7 women and 1 man; the mean age of these patients was 72.4 years (range 49–85 years). The involved sites were the head in

Table 1. Clinical Summary of 60 Cases of Sweat Gland Carcinomas

Case No.	Sex/Age, y	Site	Diagnosis†	Comment
1	M/76	Thigh	Horizontal porocarcinoma in situ	. . .
2	F/90	Abdomen	Horizontal porocarcinoma in situ	. . .
3	M/60	Chest	Horizontal porocarcinoma in situ	. . .
4	F/89	Left leg	Horizontal porocarcinoma in situ	. . .
5	M/84	Scalp	Horizontal porocarcinoma in situ	. . .
6	M/76	Forearm	Horizontal porocarcinoma in situ	. . .
7	M/86	Thigh	Horizontal porocarcinoma	. . .
8	F/12	Vulva	Horizontal porocarcinoma	. . .
9*	F/65	Chest	Horizontal porocarcinoma	Lymph node metastases
10	M/80	Right leg	Horizontal porocarcinoma	1 Recurrence + lymph node metastasis
11	M/71	Preauricular	Horizontal porocarcinoma	. . .
12	M/80	Preauricular	Horizontal porocarcinoma	. . .
13	M/58	Right knee	Horizontal porocarcinoma	. . .
14	F/71	Retroauricular	Nodular porocarcinoma	Associated with a poroma
15	F/70	Axilla	Nodular porocarcinoma	Associated with a poroma
16	M/72	Ear	Nodular porocarcinoma	. . .
17	F/92	Forehead	Nodular porocarcinoma	. . .
18	M/68	Temporal region	Nodular porocarcinoma	1 Recurrence
19	M/69	Ear	Nodular porocarcinoma	. . .
20	F/81	Back	Nodular porocarcinoma	. . .
21	F/84	Neck	Nodular porocarcinoma	. . .
22	M/85	Ear	Nodular porocarcinoma	. . .
23	F/86	Groin	Nodular porocarcinoma	. . .
24	M/75	Hand	Nodular porocarcinoma	. . .
25	F/90	Wrist	Nodular porocarcinoma	. . .
26	F/74	Cheek	Nodular porocarcinoma	. . .
27	M/80	Retroauricular	Nodular porocarcinoma	. . .
28	F/78	Scalp	Nodular porocarcinoma	2 Recurrences
29	M/82	Nose	Nodular porocarcinoma	1 Recurrence
30	M/62	Ear	Nodular porocarcinoma	. . .
31	M/54	Neck	Nodular porocarcinoma	. . .
32	F/19	Groin	Nodular porocarcinoma	. . .
33	M/41	Scalp	Nodular porocarcinoma	. . .
34	F/69	Dorso	Nodular porocarcinoma	Lymph node metastases
35	M/58	Eyebrow	Nodular porocarcinoma	. . .
36	F/77	Leg	Nodular porocarcinoma	. . .
37	M/60	Cheek	Nodular porocarcinoma	. . .
38	M/97	Retroauricular	Nodular porocarcinoma	. . .
39	M/77	Scalp	Nodular porocarcinoma	1 Subcutaneous metastasis
40	F/76	Left leg	Nodular porocarcinoma	. . .
41	F/90	Right hand	Nodular porocarcinoma	. . .
42*	F/79	Lip	Syringomatous carcinoma	. . .
43	F/84	Eyelid	Syringomatous carcinoma	. . .
44	M/48	Lip	Syringomatous carcinoma	. . .
45	F/70	Axilla	Ductal carcinoma, G1	1 Recurrence
46*	F/85	Chest	Ductal carcinoma, G1	. . .
47*	F/49	Scalp	Ductal carcinoma, G2	2 Recurrence + lymph node metastasis
48*	M/85	Chest	Ductal carcinoma, G2	. . .
49	F/60	Vulva	Ductal carcinoma, G2	1 Recurrence
50	F/77	Cheek	Ductal carcinoma, G3	. . .
51*	F/83	Forehead	Ductal carcinoma, G3	. . .
52*	F/70	Forehead	Ductal carcinoma, G3	. . .
53	M/46	Axilla	Adenoid cystic carcinoma	. . .
54	F/60	Forearm	Adenoid cystic carcinoma	. . .
55	F/81	Vulva	Adenoid cystic carcinoma	. . .
56*	F/40	Abdomen	Adenoid cystic carcinoma	. . .
57*	M/83	Chest	Adenoid cystic carcinoma	. . .
58*	F/78	Abdomen	Mucinous carcinoma	Lymph node metastases
59*	M/47	Eyelid	Mucinous carcinoma	. . .
60*	F/71	Vulva	Mucinous carcinoma	No follow-up data available

* Cases previously published.[16,18–20]

† G1 indicates well-differentiated; G2, moderately differentiated; and G3, poorly differentiated.

4 cases, chest in 3 cases, and vulva in 1 case. Clinically, lesions were nodules or plaques, with ulceration of the overlying epidermis in 3 cases. No signs of other neoplastic disease were evident in any of these patients. Two lesions recurred locally after removal, 1 of which recurred twice. Lymph node metastases occurred in 1 case (Table 1).

Histologically, these tumors were characterized by the presence of tubular structures mixed with variable amounts of cellular cords (Figure 6). The dermis was infiltrated in all cases, and the subcutaneous fat and perineural spaces were involved in 4 cases. Solid islands were observed in 4 cases. The stroma was desmoplastic in 5 cases and hyalinized in 2. Epidermal contact and ulcera-

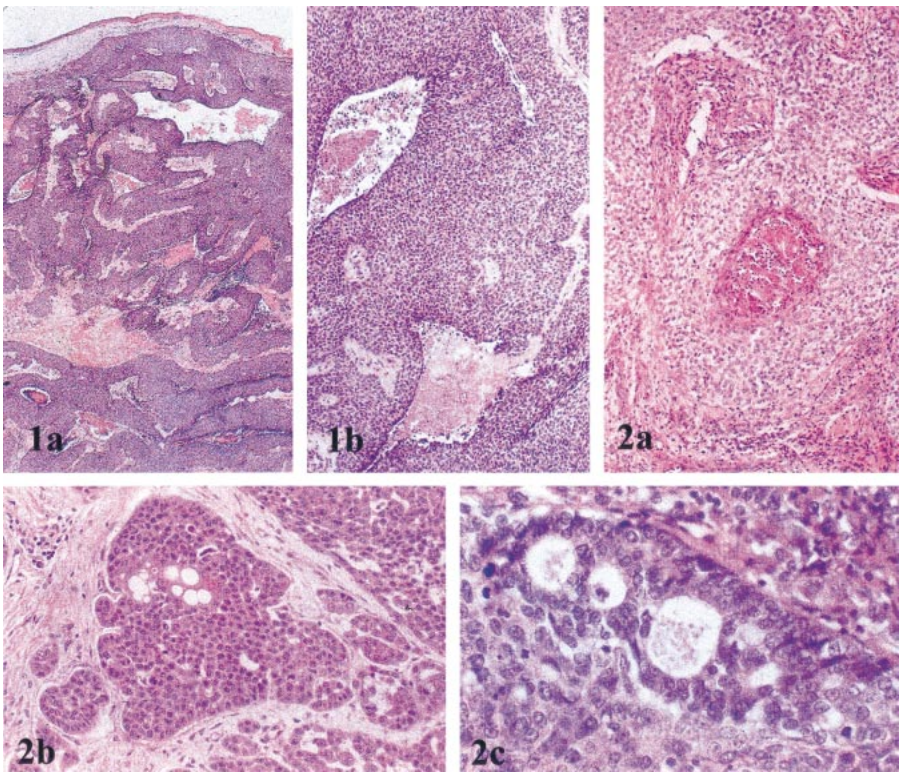

Figure 1. *Nodular porocarcinoma. Solid-cystic architecture (case 16) (hematoxylin-eosin, original magnifications ×25 [a], ×100 [b]).*

Figure 2. *Porocarcinoma. a, Case 7. Comedo-like appearance (hematoxylin-eosin, original magnification ×100). b, Case 9. Focal ductal differentiation, acrosyringium type (hematoxylin-eosin, original magnification ×250). c, Case 11. Focal ductal differentiation, dermal duct type (hematoxylin-eosin, original magnification ×200).*

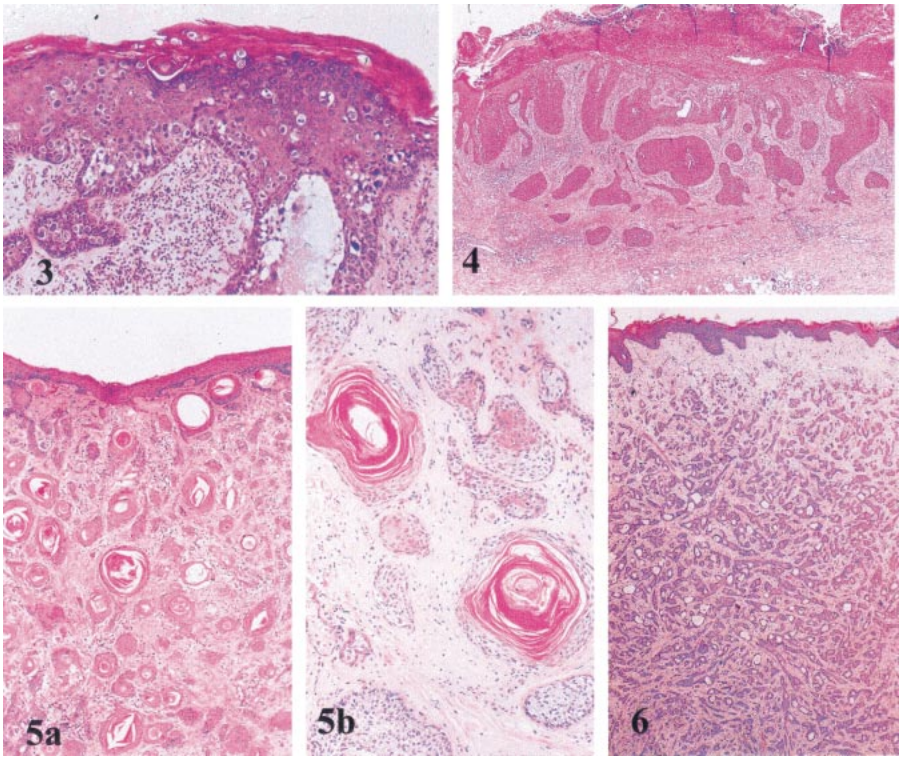

Figure 3. *Case 34. Porocarcinoma. Pagetoid epidermal pattern (hematoxylin-eosin, original magnification ×200).*

Figure 4. *Case 8. Horizontal porocarcinoma. Prominent intraepidermal component and irregular neoplastic islands infiltrating the dermis (hematoxylin-eosin, original magnification ×25).*

Figure 5. *Syringomatous carcinoma. a, Case 42. Horny cysts and tubular structures embedded in a desmoplastic stroma (hematoxylin-eosin, original magnification ×50). b, Case 44. Solid islands and horny cysts (hematoxylin-eosin, original magnification ×75).*

Figure 6. *Case 46. Ductal carcinoma. Prominent tubular formation (hematoxylin-eosin, original magnification ×25).*

tion occurred in 3 cases. Nuclear atypia was present in all cases. Mitoses were not prominent. Cases 45 and 46 were well-differentiated tumors, mainly composed of numerous tubular structures. Cases 47, 48, and 49 appeared to be moderately differentiated tumors. Case 47 was composed of numerous small tubules mixed with cellular cords, and case 48 showed large solid masses, sometimes with numerous ductal structures (Figure 7) and sometimes assuming a vague cribriform appearance. Case 49 showed ductal structures mixed with islands of cells with brightly eosinophilic, granular cytoplasm. Cases 50, 51, and 52 were poorly differentiated neoplasms composed of numerous cellular cords mixed with a small number of ductal structures.

Table 2. Immunohistochemical Findings in Sweat Gland Carcinomas*			
Tumor (No. of Cases Tested)	Cytokeratin+	CEA+	Actin+
Porocarcinomas (38)	38/38	23/38	0/38
Syringomatous carcinomas (3)	3/3	3/3	0/3
Ductal carcinomas (8)	8/8	4/8	0/8
Adenoid cystic carcinomas (5)	5/5	5/5	0/5
Mucinous carcinomas (2)	2/2	2/2	0/2

* CEA indicates carcinoembryonic antigen.

Histochemically, all cases showed intraluminal, PAS-positive, diastase-resistant material. Immunohistochemically, neoplastic cells were positive for cytokeratin and negative for actin; intratubular CEA-positive material was found in 4 cases (Table 2).

Adenoid Cystic Carcinomas (Cases 53–57)

This series included 3 men and 2 women; the mean age of patients in this group was 61.2 years (range 40–81 years). Tumors, described as cutaneous masses or nodules, were located on the chest (2 cases), abdomen (1 case), forearm (1 case), and vulva (1 case). Patients presented no salivary lesions nor any signs of neoplastic disease. No recurrences or metastases were observed after surgical removal (Table 1).

Histologically, all tumors presented the characteristic histologic appearance of adenoid cystic carcinoma, and all involved the dermis. Cells were basaloid and monomorphous; had moderately atypical, round, hyperchromatic nuclei and inconspicuous cytoplasm; and were arranged in cribriform masses or islands and in tubular structures (Figure 8, a). Solid masses or islands composed of sheets of uniform neoplastic cells occurred in 2 cases (cases 55 and 57), large cystic spaces in 1 (case 55), and necrosis of neoplastic cells in 1 (case 55). Epidermal contact was observed in 2 cases (cases 55 and 57), and subcutaneous fat involvement was evident in 2 cases (cases 54 and 57). Perineural spaces were involved by neoplastic proliferation in 1 case (case 57).

Histochemically, microcystic spaces contained eosinophilic, PAS-positive, diastase-resistant material. Immunohistochemically, cells were positive for cytokeratin, and cells lining the lumina and intraluminal material were positive for CEA (Figure 8, b). No actin-positive cells were found (Table 2).

Mucinous Carcinomas (Cases 58–60)

The 3 patients in this category included 2 women and 1 man; their average age was 62.6 years (range 47–71 years). Two lesions presented as nodules, and 1 presented as a mass; the tumors were located on the eyelid, vulva, and abdomen. No signs of other neoplastic disease were evident in these 3 patients. In case 58, a lymph node metastasis was observed 3 months after the surgical excision. No recurrence was noted in cases 58 and 59. In case 60, follow-up data were not available (Table 1).

Histologically, these tumors involved the dermis in all cases, involved the subcutaneous fat in 2 cases, and appeared to be divided into lobules by thin strands of fibrous tissue (Figure 9, a). Neoplastic cells, arranged in solid islands (cases 58 and 59) (Figure 9, b), cribriform masses (cases 59 and 60) (Figure 9, a), tubules, and small nests (case 60), floated in large pools of clear, PAS-positive, diastase-resistant material (cases 58, 59, and 60) and tended to form cystic structures (case 59). Cells were moderately atypical with round or oval nuclei and eosinophilic, vacuolated, or clear cytoplasm (Figure 9), sometimes having a signet ring appearance.

Histochemically, PAS-positive, diastase-resistant material was contained in neoplastic cells. Cytokeratin and

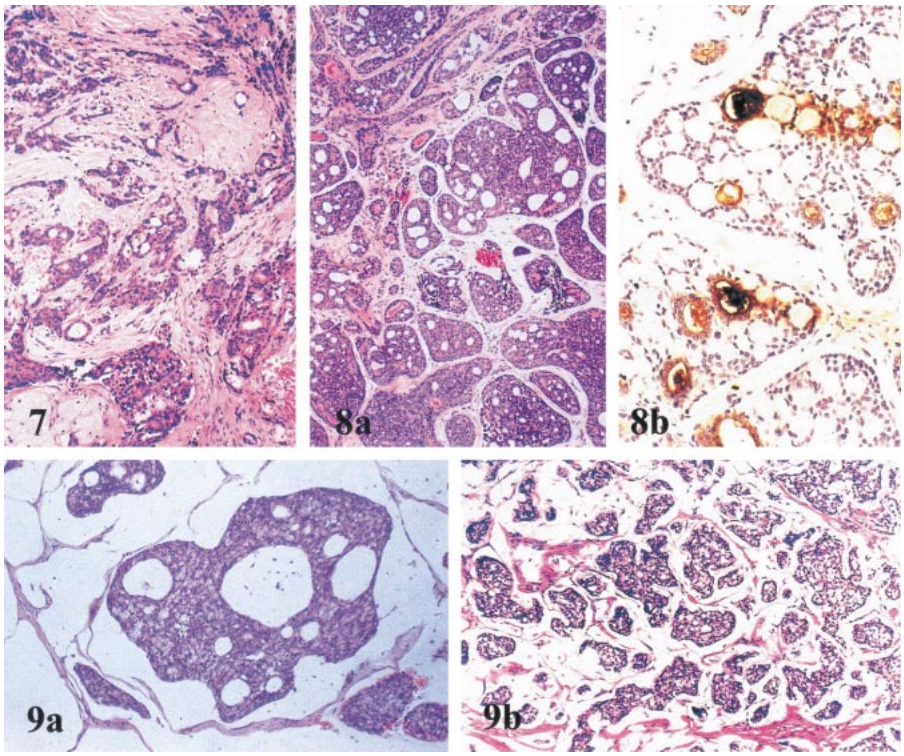

Figure 7. *Case 48. Ductal carcinoma. Tubules, solid masses, and cords (hematoxylin-eosin, original magnification ×100).*

Figure 8. *Adenoid cystic carcinoma. a, Case 55. Cribriform and tubular structures (hematoxylin-eosin, original magnification ×75). b, Case 56. Cribriform masses and lumina containing carcinoembryonic antigen (CEA)-positive material (immunostaining for CEA, original magnification ×150).*

Figure 9. *Mucinous carcinoma. a, Case 59. Cribriform islands floating in large mucin pools (hematoxylin-eosin, original magnification ×125). b, Case 58. Solid islands and mucinous material (hematoxylin-eosin, original magnification ×100).*

CEA were immunohistochemically detected in neoplastic cells. No actin-positive cells were found (Table 2).

COMMENT

The major group of tumors in this series (cases 1–41) were porocarcinomas (acrospirocarcinomas, clear cell hidradenocarcinomas).[3,13–15,21] Porocarcinoma represents a broad spectrum of epidermal, juxtaepidermal, and dermal malignant tumors composed of atypical eosinophilic and clear cells arranged in solid masses and in sheets, which frequently show cystic excavations due to extensive necrosis.[3,13,21] The classification of such tumors does not meet with general agreement. In fact, while some authors have reported such neoplasms as a unique diagnostic entity,[3,13,21] others have described them under 2 different diagnostic categories, porocarcinoma and hidradenocarcinoma, regarded as malignant counterparts of 2 different benign tumors (ie, poroma and hidradenoma, respectively).[14,15,17,22] Poroma and hidradenoma, however, appear to share several histologic features (nodular-cystic architecture, eosinophilic and clear squamous cells, and duct formation[17]) and seem to be strictly related tumors. In fact, in 1969, Johnson and Helwig[23] grouped them in the same diagnostic category (acrospiroma), and in 1990, Abenoza and Ackerman,[14] although considering them to be different neoplasms, described a benign tumor showing intermediate histologic characteristics (poroid hidradenoma). Similarly, porocarcinoma and hidradenocarcinoma appear to be closely related neoplasms, which present several overlapping histologic features, including solid-cystic pattern, eosinophilic and clear cells, central necrosis of tumor lobules, and ductal structures.[13,14,17,24] A histologic border between such tumors has not been clearly defined, and the differential diagnosis has not been adequately discussed,[14,15,17] therefore distinguishing between the two, if possible, is often difficult, especially when the tumors are not well-differentiated.

As previously noted,[13] the porocarcinomas in our series presented 2 different models of growth, horizontal and nodular, which seemed to show an analogy with superficial spreading and nodular malignant melanomas, respectively. Horizontal porocarcinomas showed a prominent intraepidermal component, extending horizontally, whereas nodular porocarcinomas presented as nodular dermal neoplasms, extending mainly in a vertical sense. In this study, tumors were arbitrarily considered horizontal porocarcinomas (13 cases) when the intraepidermal component involved at least 3 rete ridges adjacent to the dermal component. Tumors were considered to be nodular (28 cases) when the intraepidermal component was absent or involved fewer than 3 adjacent rete ridges. Six of 13 horizontal porocarcinomas did not show neoplastic cells infiltrating the dermis, although they displayed cellular atypia and a high number of mitoses. Horizontal porocarcinomas must be distinguished from some benign and malignant neoplasms. Intraepidermal poroma shows neither atypical cells nor an irregular epidermal pattern of growth.[13] Clonal seborrheic keratosis shows well-defined epidermal nests of basaloid cells with distinct intercellular bridges, without atypia or mitoses.[25] Bowen disease and squamous cell carcinoma arising in Bowen disease demonstrate a more pronounced atypism of keratinocytes, dyskeratosis,[13] and a severe architectural effacement. This is due to the neoplastic transformation of keratinocytes, rather than to an invasion by malignant cells other than keratinocytic cells. Paget disease is characterized by larger cells with ample cytoplasm, occurring singly or in clusters, which are positive for mucins.[13] Nodular porocarcinomas must be differentiated from squamous cell carcinoma, sebaceous carcinoma, and proliferating trichilemmal tumor. Squamous cell carcinomas generally originate in actin-damaged skin or in chronic ulcerative processes and show more prominent keratinization, dyskeratosis, and true horny pearls, while displaying no cystic cavity or ductal formation with PAS-positive, diastase-resistant material.[13,25] Sebaceous carcinomas show clear cells with bubbly cytoplasm due to lipid vacuoles.[13] Proliferating trichilemmal tumors are solid-cystic, well-demarcated neoplasms, whose lobules are sometimes surrounded by a vitreous layer and show palisading of their peripheral cell layer.[22] Clear cell tumors such as balloon cell melanomas and metastatic renal cell carcinomas are also in the differential diagnosis.[13] Porocarcinomas appeared as biologically aggressive tumors and are capable of recurring and metastasizing.

Syringomatous carcinoma (microcystic adnexal carcinoma; cases 42–44) represents a spectrum of infiltrative epithelial tumors that resemble syringomas. They are composed of keratinizing horny cysts, display cystically dilated and small tubules (sometimes having a tadpole appearance), are arranged in solid islands, and show no atypia or mitoses.[12] In this type of tumor, the presence of keratinizing horny cysts has been variously interpreted as a sign of follicular differentiation (microcystic adnexal carcinoma[26]) or of acrosyringeal differentiation (sclerosing sweat duct [syringomatous] carcinoma[12]). Recently, some authors have considered syringomatous carcinoma and microcystic adnexal carcinoma to be different tumors,[17] but arguments advanced in favor of such a hypothesis appear unconvincing. Syringomatous carcinoma of sweat glands may be considered as part of a wider ''transversal'' group of syringomatous tumors, which encompasses similar salivary[27,28] and mammary lesions.[29,30] Syringomatous carcinoma of sweat glands must be distinguished from syringoma and from syringomatous carcinoma of salivary glands. Syringoma generally is multiple, is limited to the upper dermis, lacks an infiltrative pattern, shows no cellular atypia or mitoses, and causes no local destruction.[22] Syringomatous carcinoma of salivary glands arises in the oral mucosa rather than in the skin.[28]

The second conspicuous group of neoplasms of our series (cases 45–52) was characterized by prominent tubular structures, as an expression of tumor differentiation toward the dermal portion of the sweat duct; such tumors have been termed *eccrine ductal adenocarcinomas*[11] or simply *ductal carcinomas.*[16] Tubules, sometimes dilated or small with small lumina, were variously mixed with solid islands, nests, and cords of neoplastic cells. Cells showed mild to marked nuclear atypia and a variable number of mitoses. Lumina contained PAS-positive, diastase-resistant, CEA-positive material. The histologic analysis of this group of tumors suggested that the wide spectrum of histologic appearances may be due to the variable grade of differentiation of tumors.[16] Two well-differentiated lesions were characterized by numerous tubules (resembling the sweat duct), mild atypia, and few mitoses (cases 45–46). Moderately differentiated tumors displayed tubules and solid islands and masses, nuclear atypia, and mitoses (cases 47–49). Poorly differentiated carcinomas showed few tubules, numerous neoplastic cords, marked atypia, and a

higher number of mitoses (cases 50–52). Some authors have considered such different expressions as belonging to distinct types of tumors (tubular carcinomas, cribriform carcinomas, and ductal carcinomas),[17] but such an elaborate scheme appears to be unnecessary, because the different morphologic appearances may be simply considered to be expressions of the variable grade of differentiation. Moreover, poorly differentiated ductal carcinomas do not fit in the proposed classification. Ductal carcinomas have to be distinguished from cutaneous metastases, especially from the breast. The most useful discriminators for making such a distinction are a detailed clinical history and a careful examination of patients.[16,31,32] Immunohistochemistry may provide useful information; in particular, diffuse positivity for CEA and negativity for gross cystic disease fluid protein 15 would favor the interpretation of primary sweat gland carcinoma over one of metastatic breast cancer.[31] Such a distinction, however, cannot rely exclusively on immunohistochemical findings because the immunophenotype of sweat gland ductal carcinomas is not specific, inasmuch as all the antigens studied (cytokeratins, CEA, S100 protein, estrogen receptor protein, progesterone receptor protein, etc) can be observed, albeit to different extents, in metastases of visceral tumors.[31–35] Ductal carcinoma appeared as a tumor that frequently recurred and was capable of metastases.

Adenoid cystic carcinoma of sweat glands is very rare. In 1998, Kato et al[36] counted 37 cases in the literature, including the tumor reported by Gomez Orbaneja et al[37] in 1973. The interpretation of such a tumor is actually controversial, in fact it has been considered as an example of ''eccrine epithelioma'' (syringomatous carcinoma).[38] Moreover, Kato et al omitted 6 cases recorded in the literature,[39] 4 reported as such[19,40,41] and 2 reported under the label of ''eccrine epithelioma,''[42] but considered as examples of primary cutaneous adenoid cystic carcinoma.[3,38,43] Therefore, excluding the case of Gomez Orbaneja et al and adding other recently reported tumors,[44–46] the total number of adenoid cystic carcinomas of the skin in the world literature is at least 45. The neoplasm has a characteristic histologic appearance and is to be distinguished from cutaneous metastases of other adenocarcinomas and, particularly, of the more frequent analogous tumors of salivary glands, which show an almost overlapping immunocytochemical profile.[47] However, if a cutaneous tumor is located in sites distant from salivary glands, it can hardly be considered metastatic, because of the extreme rarity of distant metastases from salivary adenoid cystic carcinomas.[3,48] Because its cells are basaloid, adenoid cystic carcinoma may resemble adenoid basal cell carcinoma, but the former shows no epidermal contact or peripheral palisading in neoplastic islands; however, it does display true neoplastic lumina containing PAS-positive material and common involvement of perineural spaces.[3,19,49]

Mucinous carcinomas share 2 elements with adenoid cystic carcinomas: rarity and occurrence in glands of several different anatomic sites. Actually, mucinous carcinomas seem to be more frequent, as approximately 122 cases have been reported to date.[50] The histologic appearance of such tumors is quite nonspecific, showing groups or sheets, solid or cystic, of neoplastic cells floating in large pools of mucins. In fact, an identical histologic structure can be observed in adenocarcinomas of the gastrointestinal tract, breast, lung, ovary, and pancreas.[20] Therefore, before making a diagnosis of sweat gland mucinous carcinoma, a complete investigation excluding a metastasis from a visceral cancer is necessary.[7–8,20]

In the reported series, immunohistochemical findings were similar to those reported for other sweat gland carcinomas.[31,33,35] Tumor cells were positive for cytokeratin. In 73% of tumors, CEA-positive material was found in neoplastic lumina and/or in tumor cells. No neoplastic cells positive for actin were observed in porocarcinomas, in syringomatous carcinomas, in ductal carcinomas, in adenoid cystic carcinomas, or in mucinous carcinomas, demonstrating that myoepithelial cells do not participate in the neoplastic growths of these tumors. Although it is documented that myoepithelial cells are present in the secretory portion of both eccrine and apocrine glands,[51,52] the presence and the role of such cells in sweat gland carcinomas are still controversial.[52] Myoepithelial cells have not been found in porocarcinomas, sclerosing sweat duct carcinomas, extramammary Paget disease, malignant mixed tumors, or adenosquamous carcinomas,[51–53] whereas they have been occasionally detected in mucinous carcinomas, apocrine adenocarcinomas,[51,52] and adenoid cystic carcinomas.[53,54]

Some problems are related to the classification of sweat gland carcinomas, which are currently classified on the basis of the corresponding classification of benign sweat gland adenomas.[3,13–15,17] In such a classification system, introduced by Berg and McDivitt[4] in 1968, lesions are named in accordance with the analogous benign sweat gland adenoma that they most resemble. Such an approach, however, poses several problems; for example, (1) some carcinomas have no benign counterpart and do not fit the scheme (eg, ductal carcinoma, adenoid cystic carcinoma, and mucinous carcinoma); (2) poorly differentiated carcinomas can be diagnosed only when a contiguous adenoma is found histologically; (3) histologic classification can be very complicated because adenomas are numerous and their classification is complex; and (4) terminology includes unusual and difficult terms, deriving from the terminology used for adenomas (eg, malignant acrospiroma, porocarcinoma, hidradenocarcinoma, malignant cylindroma, malignant spiradenoma, and syringocystadenocarcinoma). Recently, a classification of sweat gland carcinomas designed based on the classification of breast carcinomas has been tentatively proposed.[17] If, however, sweat gland carcinomas seem to share several histologic aspects with breast carcinomas, they also undoubtedly present important differences which make this analogy difficult. Finally, recent studies have classified sweat gland carcinomas into eccrine and apocrine tumors.[15,17] In this study, however, we avoided such designations because we found it difficult to reliably classify a tumor as eccrine or apocrine. In fact, the attribution of sweat gland neoplasms to eccrine or apocrine categories is often controversial,[15,17] because most sweat gland carcinomas seem to recapitulate sweat ducts, which are histologically similar in eccrine and apocrine glands.[3,17] In addition, no established authentic criteria are available for differentiation of an eccrine from an apocrine tumor.[14] Moreover, both eccrine and apocrine forms seem to exist in some categories.[17,32,55]

References

1. Gates O, Warren S, Warvi WN. Tumors of sweat glands. *Am J Pathol.* 1943; 19:591–631.
2. Stout AP, Cooley SG. Carcinoma of sweat glands. *Cancer.* 1951;4:521–536.

3. Cooper PH. Carcinomas of sweat glands. *Pathol Annu.* 1987;22(pt 1):83–110.
4. Berg JW, McDivitt RW. Pathology of sweat gland carcinoma. *Pathol Annu.* 1968;3:123–144.
5. El-Domeiri AA, Brasfield RD, Huvos AG, Strong EW. Sweat gland carcinoma: a clinicopathologic study of 83 patients. *Ann Surg.* 1971;173:270–274.
6. Warkel RL, Helwig EB. Apocrine gland adenoma and adenocarcinoma of the axilla. *Arch Dermatol.* 1978;114:198–203.
7. Mendoza S, Helwig EB. Mucinous (adenocystic) carcinoma of the skin. *Arch Dermatol.* 1971;103:68–78.
8. Wright JD, Font RL. Mucinous sweat glands adenocarcinoma of eyelid: a clinicopathologic study of 21 cases with histochemical and electron microscopic observations. *Cancer.* 1979;44:1757–1768.
9. Dissanayake RVP, Salm R. Sweat glands carcinomas: prognosis related to histological type. *Histopathology.* 1980;4:445–466.
10. Mehregan AH, Hashimoto K, Rahbari H. Eccrine adenocarcinoma: a study of 35 cases. *Arch Dermatol.* 1983;119:104–114.
11. Wick MR, Goellner JR, Wolfe JT III, Su WPD. Adnexal carcinomas of the skin, I: eccrine carcinomas. *Cancer.* 1985;56:1147–1162.
12. Cooper PH, Mills SE, Leonard DD, et al. Sclerosing sweat duct (syringomatous) carcinoma. *Am J Surg Pathol.* 1985;9:422–433.
13. Santa Cruz DJ. Sweat glands carcinomas: a comprehensive review. *Semin Diagn Pathol.* 1987;4:38–74.
14. Abenoza P, Ackerman AB. *Neoplasms With Eccrine Differentiation.* Philadelphia, Pa: Lea & Febiger; 1990:371–412.
15. Murphy GF, Elder DE. *Non-melanocytic Tumors of the Skin.* Washington, DC: Armed Forces Institute of Pathology; 1991:61–153. *Atlas of Tumor Pathology*; 3rd series, fascicle 1.
16. Urso C, Paglierani M, Bondi R. Histologic spectrum of carcinomas with eccrine ductal differentiation (sweat-gland ductal carcinomas). *Am J Dermatopathol.* 1993;15:435–440.
17. Requena L, Kiryu H, Ackerman AB. *Neoplasms With Apocrine Differentiation.* Philadelphia, Pa: Lippincott-Raven; 1998:589–855.
18. Carli P, Urso C, Vallecchi C. Acrospiroma maligno ad espressione clinica "zosteriforme." *G Ital Dermatol Venerol.* 1990;125:157–160.
19. Urso C, Giannini A, Rubino I, Bondi R. Adenoid cystic carcinoma of sweat glands: report of two cases. *Tumori.* 1991;77:264–267.
20. Urso C, Salvadori A, Bondi R. Mucinous carcinoma of sweat glands. *Tumori.* 1995;81:457–459.
21. Maize JC, Burgdorf WHC, Hurt MA, et al. *Cutaneous Pathology.* Philadelphia, Pa: Churchill Livingstone; 1998:483–565.
22. Elder D, Elenitsas R, Ragsdale BD. Tumors of the epidermal appendages. In: Elder D, Elenitsas R, Jaworsky C, Johnson B Jr, eds. *Lever's Histopathology of the Skin.* 8th ed. Philadelphia, Pa: Lippincott-Raven; 1997:759–761.
23. Johnson BL, Helwig EB. Eccrine acrospiroma: a clinicopathologic study. *Cancer.* 1969;23:641–657.
24. Wong T-Y, Suster S, Nogita T, Duncan LM, Dickersin RG, Mihm MC. Clear cell eccrine carcinomas of the skin. *Cancer.* 1994;73:1631–1643.
25. Kirkham N. Tumors and cysts of the epidermis. In: Elder D, Elenitsas R, Jaworsky C, Johnson B Jr, eds. *Lever's Histopathology of the Skin.* 8th ed. Philadelphia, Pa: Lippincott-Raven; 1997:685–746.
26. Goldstein DJ, Barr RJ, Santa Cruz DJ. Microcystic adnexal carcinoma: a distinct clinicopathologic entity. *Cancer.* 1982;50:566–572.
27. Johnston CA, Toker C. Syringomatous tumors of minor salivary gland origin. *Hum Pathol.* 1982;13:182–184.
28. Bondi R, Urso C. Syringomatous adenocarcinoma of minor salivary glands. *Tumori.* 1990;76:286–289.
29. Suster S, Moran AC, Hurt MA. Syringomatous squamous tumors of the breast. *Cancer.* 1991;67:2350–2355.
30. Urso C. Carcinoma siringomatoso della mammella e lesioni correlate. *Pathologica.* 1996;88:196–199.
31. Wick MR, Ockner DM, Mills SE, Ritter JH, Swanson PE. Homologous carcinomas of the breasts, skin, and salivary glands: a histologic and immunohistochemical comparison of ductal mammary carcinoma, ductal sweat gland carcinoma, and salivary duct carcinoma. *Am J Clin Pathol.* 1998;109:75–84.
32. Swanson PE, Mazoujian G, Mills SE, Campbell RJ, Wick MR. Immunoreactivity for estrogen receptor protein in sweat gland tumors. *Am J Surg Pathol.* 1991;15:835–841.
33. Swanson PE, Cherwitz DL, Neuman MP, Wick MR. Eccrine sweat gland carcinoma: a histologic and immunohistochemical study of 32 cases. *J Cutan Pathol.* 1987;14:65–86.
34. Wallace ML, Longacre TA, Smoller BR. Estrogen and progesterone receptors and anti-gross cystic fluid protein-15 (BRST-2) fail to distinguish metastatic breast carcinoma from eccrine neoplasms. *Mod Pathol.* 1995;8:897–901.
35. Metze D, Grunert F, Neumaier M, et al. Neoplasms with sweat gland differentiation express various glycoproteins of the carcinoembryonic antigen (CEA) family. *J Cutan Pathol.* 1996;23:1–11.
36. Kato N, Yasukawa K, Onozuka T. Primary cutaneous adenoid cystic carcinoma with lymph node metastasis. *Am J Dermatopathol.* 1998;20:571–577.
37. Gomez Orbaneja J, Sanchez Yus L, Diaz-Flores L, Hernandez Moro B. Adenocarcinom der ekkrinen Schweissdrusen: klinische, histopathologische, histoenzymatische und ultrastrukturelle eines Falles. *Hautartz.* 1973;24:197–202.
38. McKee PH, Fletcher CDM, Rasbridge SA. The enigmatic eccrine epithelioma (eccrine syringomatous carcinoma). *Am J Dermatopathol.* 1990;12:552–561.
39. Urso C. Primary cutaneous adenoid cystic carcinoma. *Am J Dermatopathol.* 1999;21:400.
40. Kuramoto Y, Tagami H. Primary adenoid cystic carcinoma masquerading as syringoma of the scalp. *Am J Dermatopathol.* 1990;12:169–174.
41. Chesser RS, Bertler DE, Fitzpatrick JE, Mellette JR. Primary cutaneous adenoid cystic carcinoma treated with Mohs micrografic surgery toluidine blue technique. *J Dermatol Surg Oncol.* 1992;18:175–176.
42. Sanchez NP, Winkelmann RK. Basal cell tumor with eccrine differentiation (eccrine epithelioma). *J Am Acad Dermatol.* 1982;6:514–518.
43. Urso C, Bondi R. Eccrine epithelioma: an enigma or a chimera? *Am J Dermatopathol.* 1992;14:179–180.
44. Salzman MJ, Eades E. Primary cutaneous adenoid cystic carcinoma: a case report and review of the literature. *Plast Reconstr Surg.* 1991;88:140–144.
45. Chang SE, Ahn SJ, Choi JH, Sung KJ, Moon KC, Koh JK. Primary adenoid cystic carcinoma of skin with lung metastasis. *J Am Acad Dermatol.* 1999;40:640–642.
46. Weekly M, Lydiatt DD, Lydiatt WN, Baker SC, Johansson SL. Primary cutaneous adenoid cystic carcinoma metastatic to cervical lymph nodes. *Head Neck.* 2000;22:84–86.
47. Wick MR, Swanson PE. Primary adenoid cystic carcinoma of the skin: a clinical, histological, and immunohistochemical comparison with adenoid cystic carcinoma of salivary glands and adenoid basal cell carcinoma. *Am J Dermatopathol.* 1986;8:2–13.
48. Headington JT, Teears R, Niederhuber JE, Slinger RP. Primary adenoid cystic carcinoma of the skin. *Arch Dermatol.* 1978;114:421–424.
49. Cooper PH, Adelson GL, Holthaus WH. Primary cutaneous adenoid cystic carcinoma. *Arch Dermatol.* 1984;120:774–777.
50. Bellezza G, Sidoni A, Bucciarelli E. Primary mucinous carcinoma of the skin. *Am J Dermatopathol.* 2000;22:166–170.
51. Maiorana A, Nigrisoli E, Papotti M. Immunohistochemical markers of sweat gland tumors. *J Cutan Pathol.* 1986;13:187–196.
52. Wach F, Hein R, Kuhn A, Landthaler M, Krieg T, Eckert F. Immunohistochemical demonstration of myoepithelial cells in sweat gland carcinomas. *Br J Dermatol.* 1994;130:432–437.
53. Biermat W, Kordek R, Wozniak L. Diagnostic significance of the myoepithelial cells in the benign and malignant sweat gland tumors. *Pol J Pathol.* 1996;47:7–11.
54. Wassef W, Thomas V, Deffrennes D, Lacau Saint-Guily J. Les carcinomes adénoides kystiques cutanés primitifs: etude histologique et ultrastructurale de deux cas localisés au conduit auditf externe. *Ann Pathol.* 1995;15:150–155.
55. Ansai S, Koseki S, Hozumi Y, Kondo S. An immunohistochemical study of lysozyme, CD-15 (Leu M1), and gross cystic disease fluid protein-15 in various skin tumors: assessment of the specificity and sensitivity of markers of apocrine differentiation. *Am J Dermatopathol.* 1995;17:249–255.